

Neural-Scan Helps Identify Piriformis Syndrome

2002 - Presented: American Society of Regional Anesthesia and Pain Medicine (ASRA) Scientific Conference

2005 - American Association of Sensory Medicine (ASSM) Conference

Randall Cork, MD, PhD Chairman of the Department of Anesthesiology and Director of Pain Medicine, Louisiana State University Health Sciences Center, Shreveport, LA

Summary: This retrospective study of 50 patients found an 80% probability of concomitant piriformis syndrome when the Neural-Scan detected abnormal L5 and S1 dysfunction on the ipsilateral (same) side.

INTRODUCTION

Piriformis Syndrome has been documented as a primary and/or contributory cause for sciatica and low back pain (1, 2, 3, and 4). Botulinum toxin-A™ is used by both medical and surgical specialists to successfully treat dystonic muscle disorders (6, 7, 8). During a seven-month period, 50 patients in our practice were diagnosed with piriformis syndrome and underwent intrapiriformis Botulinum toxin-A™ injection with remarkable pain relief at 6 to 8 weeks follow-up.

METHODS

A retrospective review of 50 patients of the Pain Management Service at Louisiana State University Health Sciences Center who received intrapiriformis (Botulinum toxin-A™) injection was performed. All patients were taking one of the following analgesics: NSAIDs, tramadol, or long acting opioids, or gabapentin. All patients gave informed consent for this procedure. The demographic characteristics and relevant past medical histories of our study group are given in Table I and Table II respectively. Our diagnostic criteria for piriformis syndrome include the following: Gluteal pain with or without pain radiating down the affected leg in the distribution of sciatic nerve, muscle spasms/cramps/pull in leg muscles, positive Beatty's Maneuver (9) with or without the presence of tenderness, and L5, S1 or both L5 and S1 sensory nerve root hypoesthesia, as measured with the Neural-Scan Small-Pain-Fiber Nerve Conduction Study (SPF-NCS) at 250 Hz (10)(26).

Botulinum-toxin A (Botox™, Allergan™) is a standardized preparation that comes in powder form. Botulinum toxin-A™ 100 units mixed in 5 cc of preservative-free normal (0.9 N) saline was used for each intrapiriformis injection. The fluoroscopic technique performed is as follows: In a prone patient, the greater trochanter of the femur and the lower part of sacrum or sacroiliac joint of the same side is visualized, and a marker (e.g., a large hemostat) is placed on an imaginary line connecting the two. This represents the anatomical location of the piriformis muscle. Injection can be performed anywhere on this line, but the selected site was closer to sacrum where the base of piriformis muscle lies. Injections were made over bone to avoid possible injury to the sciatic nerve and pelvic structures. A 22-gauge 3.5inch spinal needle was advanced until the characteristic loss of resistance was felt as the needle penetrates the piriformis fascial sheath. Omnipaque 1ml was then injected to obtain a piriformis myogram. After x-ray analysis showed negative for aspiration of blood, Botulinum toxin-A™ was then injected. (See X-ray below).

RESULTS

The outcome measures of pain intensity were Visual Analog Scales (VAS) (11), and modified McGill (12) scores, and the outcome measures of disability were Oswestry (13), and Roland-Morris Disability Scale (14) scores. The data below were obtained prior to treatment, and at 6-8 weeks follow-up after the procedure. VAS prior treatment was mean \pm SEM 8.8 ± 0.151 , compared to post treatment 4.53 ± 0.242 ($p < 0.05$). Table III shows the change in McGill, Roland-Morris and Oswestry scores from before to after treatment. All patients reported a reduction in pain scores. VAS pain scores in the study population were 8.87 ± 0.15 prior to treatment and 4.5 ± 0.2 after treatment ($p < 0.01$). McGill scores were 40.6 ± 3.04 before and 21.5 ± 2.51 after the injection ($p < 0.01$). Oswestry scores changed from 25.9 ± 1.26 to 11.7 ± 1.02 ($p < 0.01$) and Roland-Morris scores decreased from $16.0 \pm .935$ to 20.6 ± 1.02 ($p < 0.01$). Lumbar SPF-NCS showed hypoesthesia in nerve roots L5 in 7/48, S1 in 9/48 and both L5 and S1 in 32/48 patients.

DISCUSSION

Botulinum toxin-A™ is a 150 Kda protein produced by *Clostridium Botulinum*. It is a neurotoxin, which acts presynaptically by inhibiting the release of acetylcholine, thus leading to functional denervation of muscle (15). This effect lasts up to 6 months. In 1989, FDA approved its use for the treatment of strabismus, blepharospasm, and hemifacial spasm (ref). Botulinum toxin-A™ has been on the market for a while now, but its use in pain patients has gained popularity only recently (16, 17, 18, 19).

The piriformis muscle is a pyramidal muscle that arises as three digitations from the ventrolateral aspect of the sacrum from S1-S4, gluteal surface of ilium near the posterior inferior iliac spine and the anterior capsule of the sacroiliac joint. It passes through the greater sciatic foramen on its lateral trajectory to its tendonous insertion on anterior/medial aspect of the greater trochanter of the femur. Piriformis syndrome is a secondary cause of sciatica due to compression and/or irritation of sciatic nerve compressed by the contracted piriformis muscle. Its signs and symptoms can be explained by the proximity of the muscle to sciatic nerve at the sciatic notch. There are six possible relationships between the piriformis muscle and the sciatic nerve (23). Most commonly, the nerve is anterior and below piriformis muscle. The patient complains of pain, numbness and/or weakness in L4, L5 or S1 distributions. These may be associated with localized tenderness in piriformis muscle itself. Alternatively, pain due to piriformis spasm can also be felt as a deep, aching type of pelvic pain on the same side without signs and symptoms of sciatica.

As the piriformis muscle is a lateral rotator of hip flexion and assists in abduction, active muscle contraction can lead to pain reproduction (Beatty's maneuver (9)). These physical signs if present are useful in differentiating piriformis syndrome, from sciatica due to other causes alone.

SPF-NCS provides a reproducible (< 0.2 mA) functional assessment of the peripheral sensory nervous system by measuring the voltage intensity which initiates membrane potential changes, to propagate a nerve impulse.

One problem with the diagnosis of the piriformis syndrome has been the lack of consistent objective diagnostic findings. We have found lumbar SPF-NCS reliable in detecting sciatica and, when correlated with signs and symptoms can confirm the diagnosis of piriformis syndrome.

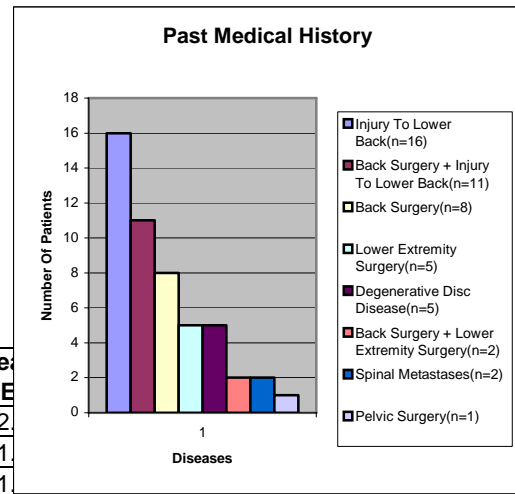
Our study shows an association of piriformis syndrome with low back injury and/or surgery, degenerative disc disease, total hip surgery, spinal metastases and pelvic surgery. Two of our patients had piriformis syndrome after hard falls to the floor. We speculate that piriformis muscles may go into spasm either secondary to irritation of its nerve supply, sciatic nerve irritation, as in disc disease, lumbosacral radiculitis, or surgery in its vicinity, such as in total hip replacement, pelvic surgery, etc.

A variety of therapeutic approaches have been suggested for the management of piriformis syndrome (20, 21, and 22). These include conservative measures such as analgesics, application of heat, osteopathic manipulation, stretching exercises and even surgical resection of the piriformis muscle (23). Except for the latter, none of these modalities offer significant pain relief, and surgery is associated with morbidity. Perisciatic injection of steroids (24) and caudal epidural steroid injection for piriformis syndrome (25) have been described, as well as injection of local anesthetics and steroids in the muscle belly, but at present there are no outcome data which show their efficacy. Our study shows that intrapiriformis Botulinum toxin-A™ injection significantly reduces pain and disability for at least 6 and up to 8 weeks. All of the patients who underwent Botulinum toxin-A™ injection to piriformis muscle reported at least a 45% reduction in pain as well as improvement in their disability scores. Intrapiriformis Botulinum toxin-A™ injection can be performed easily and quickly (< 10 minutes) under fluoroscopic guidance, does not require EMG needle placement or the use of a nerve stimulator, and is less invasive than surgery. The technique for intrapiriformis injection described in this paper can be learned easily. After performing a few injections, one easily appreciates the characteristic feel of the needle entering the piriformis sheath. Intrapiriformis Botulinum toxin-A™ injection is an effective treatment for Piriformis Syndrome.

TABLE I: DEMOGRAPHIC CHARACTERISTICS OF 50 PATIENTS

Age (years)	51.76 +_ 1.7268
Weight (lbs)	180.82 +_ 5.15
Height (inches)	66.52 +_ 0.4959
Female	34
Male	16

FIGURE 1: PAST MEDICAL HISTORY (N=50)

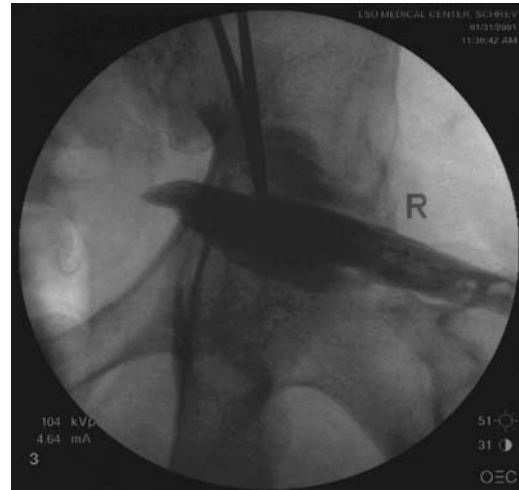
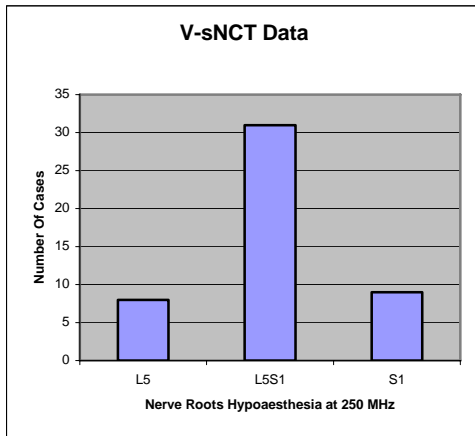


	Before Treatment Mean±SEM	After Tre: Mean±SE
McGill	40.629±3.048	21.555±2
Roland Morris	16.074±0.935	11.740±1
Oswestry	25.963±1.260	20.666±1

TABLE II: MCGILL, OSWESTRY, ROLAND-MORRIS---BEFORE AND AFTER (N=27)

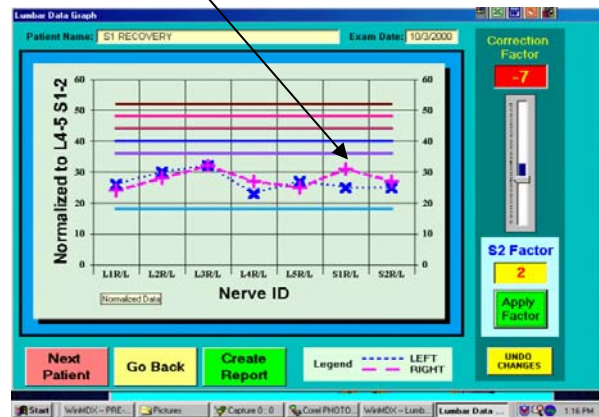
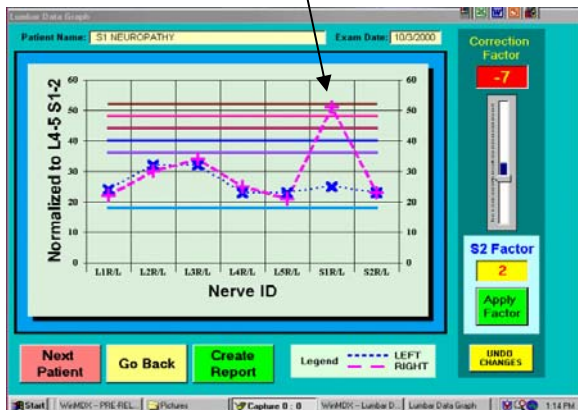
Figure 2: SPF-NCS Data (n= 48)

X-Ray



SPF-NCS Graph I: Right S1 severe rated dysfunction Botulinum injection.

SPF-NCS Graph II: S1 recovery after piriformis



Address correspondence and reprint requests to Sarosh Salemi, M.B.B.S., Department of Anesthesiology and Pain Management, Louisiana State University Health Sciences Center, 1501 King's Highway, Shreveport, Louisiana 71130. Address email to: srm225@hotmail.com

REFERENCES

Zia Durrani,MD, Alon P. Winnie, MD. Piriformis Muscle Syndrome: Under-diagnosed Cause of Sciatica: Journal of Pain and Symptom Management; Vol 6 No.6, August 1991.

Pace, J. B., and Nagle, D: Piriformis Syndrome. Western Journal of Medicine: 124:435-9, June 1976.

Hallen R. P.: Sciatic Pain and Piriformis Muscle Syndrome. Postgraduate Medicine: 1983;74:69-72.

John R. Parziale, MD, Thomas H. Hudgins,MD.; The Piriformis Muscle Syndrome. The American Journal of Orthopedics, December 1996.

Retzlaff E. W.; The Piriformis Muscle Syndrome. The Journal of American Osteopathic Association: 1974 Jun; 73(10): 799-807.

Joseph Jankovic, MD,: Therapeutic Uses of Botulinum Toxin: The New England Journal of Medicine: April 25, 1991.

Joseph K. C. Tsui: Botulinum toxin as a therapeutic agent: Pharmacological Therapeutics: 1996: 72(1): 13-24.

N.Mahant MBBS FRACP: The current use of botulinum toxin. Journal of Clinical Neuroscience: 2000 Sept: 7 389-94.

Beatty R.A.; The piriformis muscle syndrome: A Simple Diagnostic Maneuver. Neurosurgery: 1994; 34: 512-4;discuss

Cork, R. et al: Single-Electrode SPF-NCS and Nerve-Root Pathology: Regional Anesthesiology and Pain Medicine Vol. 24 No 3 May 1999

Scott, J and Huskisson, EC, : Graphic Representation of Pain. Pain: 2 (1976) 175-184.

Ronald Melzack: The McGill Pain Questionnaire. Pain: 1(1975) 277-299.

Jeremy C T Fairbanks, FRCS et al. The Oswestry Low Back Pain Disability Questionnaire: Physiotherapy, 1980; 66:271-273.

Roland M, Morris R. A Study of the Natural History of Low Back Pain - Part I: Development of a Reliable and Sensitive Measure of Disability in Low Back Pain. Spine: 1983;8; 141-144.

P. Hambleton. Botulinum Toxin: Structure and Pharmacology. Eur. Arch of Oto-Rhino-Laryngology: Supp: 1994: S 200-2.

William P. Cheshire; Botulinum Toxin in the Treatment of Myofascial Pain Syndrome: Pain 59(1994) 65-69.

Barry M. Guyer, MA, and MB: Mechanism of Botulinum Toxin-A in the relief of chronic pain. Current Review of Pain: 1999, 3:427-431.

Mauro Porta; A Comparative Trial of Botulinum Toxin-A and Methylprednisone for the Treatment of Myofascial Pain Syndrome and Pain From Chronic Muscle Spasm: *Pain* 85 (2000) 101-105.

Jose J. Monsivais, MD, FACS; Botulinum Toxin in Painful Syndromes: *Hand Clinics*: Vol 12. No. 4 November 1996.

Wyant G.D. Chronic Pain Syndromes and Their Treatment III. The Piriformis Syndrome: *Canada Anesthesiology Society Journal*: 1979;26:305-308

Pamela M. Barton. Piriformis Syndrome: A Rational Approach to Management: *Pain* 47(1991) 345-352.

Carles Steiner, DO, FAAO et al. Piriformis Syndrome: Pathogenesis, Diagnosis and Treatment. *The journal of American Osteopathic Association*: 87(4): 318-23. April 1987

Ludvig Fjeld Solheim; The Piriformis Muscle Syndrome; Sciatic Nerve Entrapment Treated with Section of the Piriformis Muscle: *Acta orthop. Scand.* 52, 73-75,1981.

M.Hanania; Perisciatic Injection of Steroid for the Treatment of Sciatica Due to Piriformis Muscle Syndrome. *Regional Anesthesia & Pain medicine*: 1998 Mar-Apr: 23(2): 223-8

Vildan Mullin, MD and Michael Rosayro, FFARCS: Caudal Steroid Injection for Treatment of Piriformis Muscle Syndrome: *Anesthesia/Analgesia* 1990;71;705-7.

Cork, Randall, PhD. MD. et. al. Predicting Nerve Root Pathology With Voltage-actuated Sensory Nerve Conduction Threshold. *Internet Journal of Anesthesiology*: Nov. 2002